

# Inbreeding Depression in Captive White Tigers: Methods for Purifying Tiger Lineages

Deborah Marlene Warrick\*

## Introduction

White tigers, once considered rare, currently number in the hundreds in private animal compounds and zoos. Captured on May 27, 1951 by the Maharaja of Rewa in India, one of the first white tigers named Mohan (Mohan translates to "Enchanter") unwillingly bartered its mangrove swamps for an urban jungle, resulting in the white tiger's dubious relationship with mankind. Mohan's mother and siblings were destined for another fate, however; they were shot for their magnificent orange hides.

Genetic concepts, specifically the existence of dominant and recessive alleles, were unknown to the Maharaja. When Mohan was bred to an orange, wild-caught female at Govindgarh palace, the resulting F1 offspring were all of the orange phenotype and carriers of the white allele. It was only when Mohan was bred back to one of his heterozygous offspring (Radha) were white tiger cubs produced, and the white tiger line in captivity was born.

To continue the reproduction of only the desired white phenotype, white tigers were inbred either brother to sister, father to daughter, or mother to son. This type of unscientific propagation led to inbreeding depression in white tigers, and deformities began to surface. Cub mortality rate continued to rise until not a single white tiger survived to reproduce. For the past four decades, Govindgarh has been devoid of its Royal White Tigers.

When Mohan was captured, the Maharaja's goal at Govindgarh Palace was to produce additional white tigers for his collection, so Mohan was bred to an orange tigress named Begum (Roychoudhury, 1979). The F1 offspring, which included ten cubs in three litters, were all heterozygotes. The white phenotype was not produced until a cub named Radha from Begum's second litter was bred back to Mohan. Radha produced 14 cubs in four litters, three of which were orange and eleven of which were of the white phenotype. This was the first line of white tigers to be born in captivity.

Descendants of Mohan's line were dispersed in India to the Delhi Zoological Park, the Calcutta Zoological Gardens, the National Zoo in Washington, D.C., and to England's Bristol Zoo. The degeneration in fitness from inbreeding all captive white tigers resulted in sterility or reduced fecundity, shortened lifespan, vision abnormalities, shortening of limbs, twisted necks, kidney deformities, weakened immune systems, poor lactation in females, and numerous stillbirths.

Mohan was not the only white tiger brought into captivity, nor was he the first. The Calcutta Zoo had a white tiger on exhibit in 1920, and unrecorded numbers of white tigers lived in the wilds of Assam, India (Tilson, 1987). Contrary to common belief, the white tiger in India during this time period was not a rare mutation, and was observed in the wild by reputable sources for over 50 years before Mohan's capture. At least 17 white tigers were shot in India from 1907-1933, reported by the Bombay Natural History Society (Tilson, 2010).

White tigers arrived in the U.S. in 1960, when John Kluge of the Radio Corporation of America (RCA) purchased a white tigress named Mohini from the Maharajah for \$10,000 as a gift to the National Zoo. The tigress was officially presented to President Eisenhower on the White House lawn. Mohini was bred to a heterozygous male (her brother, Samson), also transported from India. All inbred progeny were further inbred to produce more white tigers. Decades of incestuous breeding of white tigers to increase their numbers has resulted in inbreeding depression, decreasing the fitness of the population of white tigers in the United States (Devraj, 2000). After 1960, white tigers were commonly sold out of India into circuses and zoos.

The Henry Doorly Zoo in Omaha, NE developed a white tiger-breeding program in the 1980's. However, AZA-accredited zoos decided to phase out the Bengal tiger subspecies and especially white tigers, which they considered an aberration, so the Zoo abandoned the project and sold their tigers to exotic animal dealers, who in turn sold white tigers into the private sector. Fifty years after the first white tigress arrived on US soil, there are now several hundred white tigers in captivity in the U.S. This translates into 9 generations since Mohini, and the white gene is no longer rare.

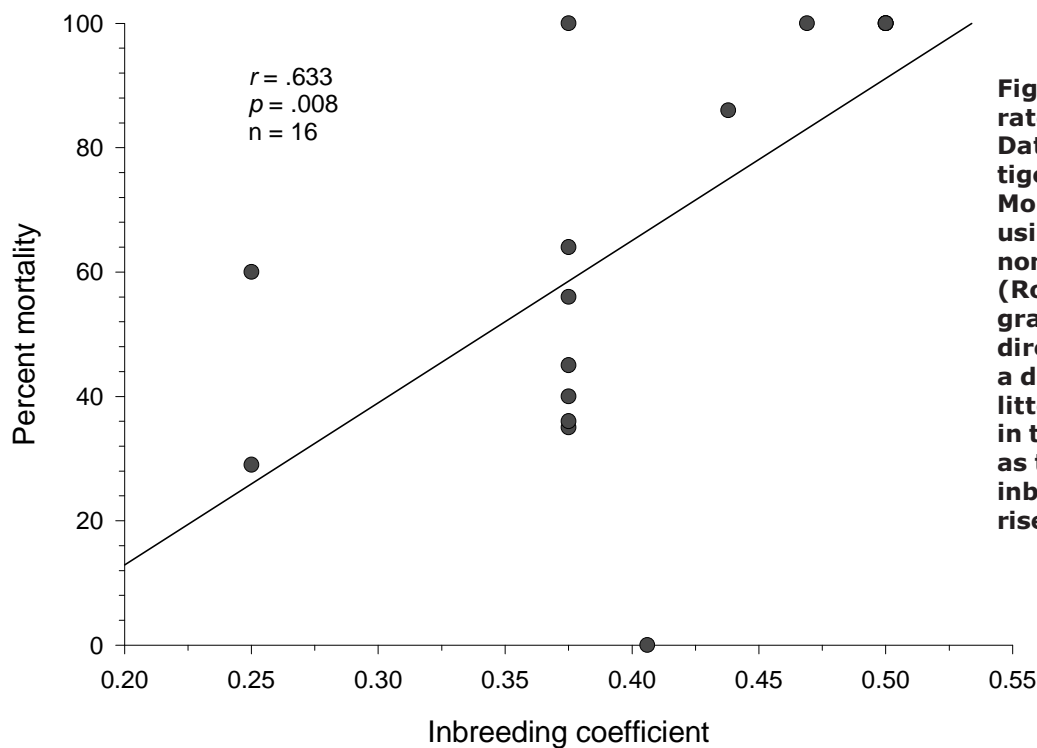
## Mendelian Genetics and the White Tiger

When a homozygous recessive white tiger is bred to an orange tiger, which is homozygous dominant, the resulting offspring (F1) are heterozygous and exhibit the orange color, since the allele for the orange phenotype is dominant (an example of complete dominance).

When two heterozygous tigers are bred, 25% of the resulting offspring (F2) will consist of the white

\*See images on web version @ [www.zoosprint.org](http://www.zoosprint.org)

\*Founder/CEO, St. Augustine Wild Reserve, St. Augustine, FL 32085, USA.  
[www.staugustinewildreserve.org](http://www.staugustinewildreserve.org)



**Figure 1. Percent mortality rate in newborn tiger cubs. Data collected from all tiger matings involving Mohan from 1951-1979, using tiger cubs that died non-accidentally (Roychoudhury 1978). The graph shows that there is a direct correlation between a decrease in the average litter size and an increase in the cub mortality rate, as the value of the inbreeding coefficient rises.**

phenotype. When a white tiger is crossed with a heterozygous tiger, 50% of the offspring will be white. Finally, when a white tiger is crossed with another white tiger, 100% of the offspring will be white and will carry both copies of the recessive allele (Russell, 2006).

*Leucism vs. albinism:* White tigers are not albinos; they are leucistic. Albinism is characterized by the absence of pigment in the skin, hair and eyes due to an enzyme defect involved in melanin production (Mills, *et al.*, 2009). Albinos have red eyes due to the underlying blood vessels showing through. Albinism results from inheritance of recessive alleles. There are no known albino tigers.

Leucism is characterized by a reduction in all types of skin pigment, not just melanin. Leucistic vertebrates, such as white tigers, carry the recessive "Chinchilla" allele. The hair shaft lacks normal bands of pigments and may be pigmented only at the top. This allele is known as the "inhibitor" allele because it inhibits pigment production. Leucistic tigers have colored eyes, although the pigmentation is reduced and their eyes are blue, unlike their orange counterparts who have amber eyes. They have black, brownish or gray stripes on a cream or white background, and their noses and foot pads are pink.

*Inbreeding Depression:* Inbreeding is defined as the mating of a pair of animals who are related through one or more common ancestors. The more closely related the animals are, the greater the degree of inbreeding, and the greater the loss of hybrid vigor. Examining both sides of the spectrum, the most

severe form of inbreeding is self-fertilization, which occurs in some plants. In mammals, the most severe form of inbreeding occurs when brother and sister are bred, or if parents breed with their offspring.

Deleterious effects of inbreeding on the growth rates of eastern mosquito fish (*Gambusia holbrooki*) have also been documented. Progeny which resulted from brother-sister matings experienced a 56% lower growth in numbers over mosquito fish progeny which resulted from unrelated pairs (Frankham 2003).

Inbreeding doesn't always cause negative growth rates or deformities. Studies of the northern elephant seal (*Mirounga angustirostris*) showed that despite the population decline to only 20 or 30 specimens, this species has recovered to well over 100,000 animals. There are two reasons for this unusual effect. First, the elephant seal decline was not from inbreeding, but from overhunting by humans. Secondly, the inbreeding which ensued after the species became protected did not result in a negative growth rate. Inbreeding did not affect the elephant seal since it has a high growth rate. Species with low growth rates, like tigers, tend to be more susceptible to deleterious effects from inbreeding (Frankham 2003).

Genetic problems in vertebrates usually occur due to mutations or inbreeding. Mutations are the result of incomplete or inaccurate copying of DNA as it prepares for cellular division. The incomplete division of the chromosomes in sperm or ova may also lead to a mutation, since additional genetic



**Figure 2. Example of bull-dog face in an adult white tiger.  
Courtesy of Turpentine Creek Wildlife Refuge/Scott Smith Images**

material is present in the zygote. The process of aging or exposure to free radicals (byproducts of UV light exposure or cellular metabolism) can also trigger DNA mutations.

Birth defects may be structural, environmental, or nutritional. In structural birth defects, trauma may interfere with the formation of a body part. An environmentally caused birth defect may include exposure to parasites, bacteria or viruses, present during development of a particular body system. Drugs may also be teratogenic, and existing illnesses in the mother can also be a factor in creating birth defects.

Felines require elevated levels of arginine, taurine and arachidonic acid (Gates, Margaret 2010). Additional arginine is required since felines lack pyrroline-5-carboxylate synthase, an enzyme which synthesizes ornithine, an arginine precursor. Arginine is essential for protein synthesis, detoxification of ammonia and enhanced T-cell function. A deficiency in taurine may cause cardiomyopathy, retinal degeneration and reproductive failure. Arachidonic acid (an essential fatty acid) deficiency may result in reduced fecundity, dry coat, dermatitis and pyoderma. Borderline deficiencies may go unnoticed in the adult animal, but if the female becomes pregnant, those same borderline deficiencies may cause birth defects or fetal death (Jones, 2010).

A mathematical formula exists which reflects the degree of inbreeding, known as the inbreeding coefficient, which is the probability that genes in a certain animal are identical by descent, i.e., both alleles at a locus are descended from a single allele that is present in one of the ancestors common to the sire and dam. An animal which is not inbred has an inbreeding coefficient of zero, while a

seriously-inbred animal has an inbreeding coefficient of one (Fig. 1).

It has long been known that inbreeding, known to increase the degree of homozygosity of gene pairs in a given population, can lead to congenital malformations. The white tiger is especially susceptible to inbreeding maladies, since the allele for the white coloration possesses many deleterious qualities, including vision abnormalities. They also are larger than orange tigers and experience an accelerated growth rate, although it is unknown as to what effect these attributes may have in tiger populations. Increased size and growth rate may vary the gene pool. This "body size allele" may allow the tiger to adapt to changing conditions (Tilson 1987).

*Bull-dog Face:* Some white tigers in the North American line suffer from a facial deformity known as bull-dog face, which is a distortion of the head, lacking bone development in the middle facial and upper jaw portion (Fig. 2\*). The condition is characterized by a snubbed nose, domed head, jutting jaw, and wide-set eyes with an indentation between the eyes. This defect is related to the original germ cells and is not sex linked. A poor diet may also be responsible for some of the described traits.

*Prion Disease:* In rodents, certain pigmentation mutants are known to develop brain spongiform changes from prions, which are proteinaceous infectious particles. Prions propagate by transmitting a misfolded protein. As with viruses, the prion does not self-replicate. It induces existing polypeptides in the host animal to take on the new form, causing spongiform encephalopathies which are fatal neurological diseases. White tigers, because of their pigment

variant, can be more susceptible to prion disorders than orange tigers. It has been suggested that pigmentary gene mutations and brain spongiform degeneration may be related (Hernandez, 2009). Spongiform encephalopathies result from the accumulation of misfolded prion proteins in the central nervous system (CNS) of both humans and animals, which cause neurodegeneration of the CNS. The best known spongiform encephalopathy is Bovine Spongiform Encephalopathy (BSE, or mad cow disease). The prion protein gene is located on the same chromosome as several pigmentation genes. It is speculated that certain genes responsible for pigmentation cause the prion protein to misfold. Brain spongiform degeneration was documented in four related white tigers housed in the United Kingdom at the Bristol Zoo (Pearson 1980). This indicates a higher predisposition of white tigers to the disease when compared to orange tigers. The ingestion by these tigers of BSE-infected meat was not considered significant, since very few BSE cases have been documented among tigers housed in the UK.

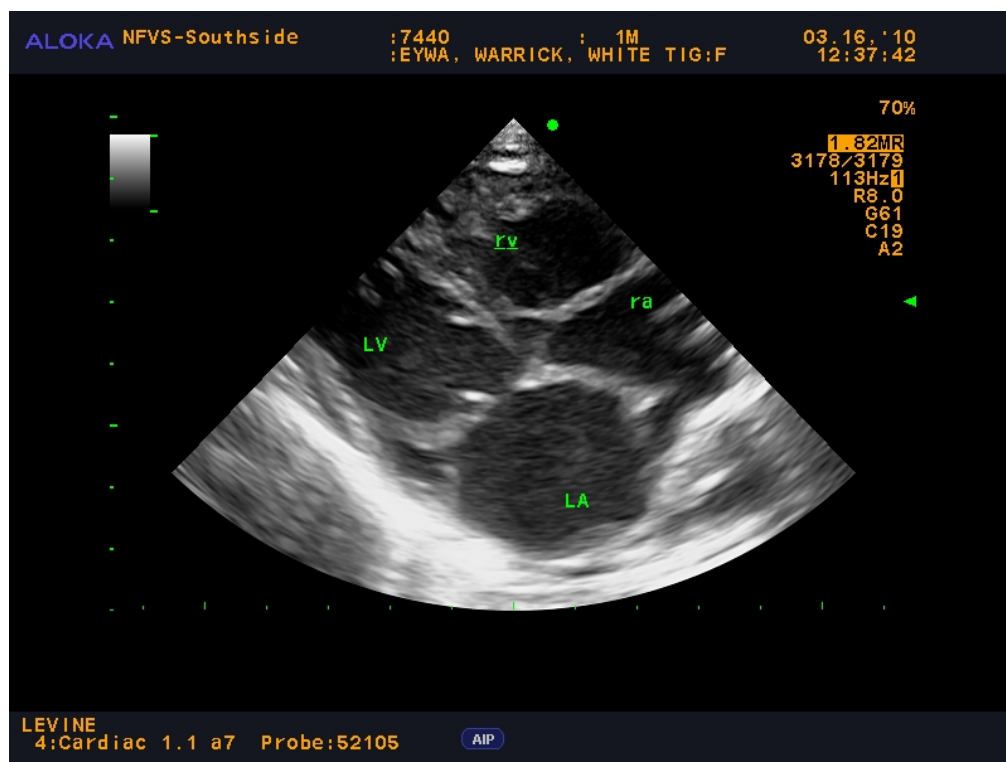
**Oral Eosinophilic Granuloma:** Found on the hard or soft palate of 16 tigers in this study (four were white and were related); eosinophilic granulomas are lesions consisting of flat or slightly-raised ulcers (Sykes, *et al.*, 2007). These lesions can also be found on the thigh region of felines. Symptoms include appetite loss, salivation and dysphagia. Treatment of these tigers included surgical removal of the ulcers, antibiotics, cryotherapy and corticosteroids, the latter of which was effective, but the condition recurred once the corticosteroid therapy was stopped. Oral lesions are considered

to be allergic disorders. Genetics may play a role in this disorder, since the allergy may be inherited.

**Chronic Regurgitation in a four-week old white tiger:** A three-month-old male white tiger, weighing half as much as its littermates, was treated at Kansas State University Veterinary Medical Teaching Hospital (Ketz, *et al.*, 2001). When the tiger was only four weeks of age, it exhibited difficulty in swallowing its formula. Each time it was fed, the tiger regurgitated its formula. The problem worsened when solid food was offered to the cub at the age of two months. A vascular ring anomaly was diagnosed, which occurs when aortic arches IV and VI develop abnormally during embryogenesis. Esophagoscopy revealed a persistent right aortic arch constricting the esophagus, which had several fibrous adhesions encircling it. Surgery corrected the problem and the tiger grew to full size.

In canines, this condition is known to be hereditary. Since white tigers are inbred, a genetic cause for this white tiger's condition cannot be eliminated.

**Strabismus:** Strabismus is associated with the white allele, and not just inbreeding. There are numerous syndromes and diseases that are associated with the pigmentary system (Mills, *et al.*, 2009), including strabismus, in which the nerves of the visual pathways are routed to the wrong side of the brain. When the neurons pass from the retina to the brain and reach the optic chiasma, some cross and some do not, so visual images are projected to the wrong hemisphere of the brain. This visual pathway abnormality in white tigers causes a problem with spatial orientation; they



**Figure 3. Ultrasound image revealing a large membranous VSD (0.5cm). Image shows moderate to severe aortic insufficiency, and moderate mitral valve and tricuspid valve insufficiencies.**

bump into objects until they learn to compensate. White tigers cannot see as well as normal tigers and suffer from photophobia, similar to albinos. White tigers with crossed eyes are not always born that way; they may develop the condition later in life.

Star-gazing has been observed in white tigers, although this may also be due to a nervous disorder that is not specific to the white mutation (Tilson, 1987). Parkinson's syndrome has also been observed in white tigers (Rathore and Khera, 1981).

*Heart Conditions:* Cardiac defects, including ductus arteriosus and atrial septal defects, have been observed in newborn white tiger cubs (Tilson, 1987). Two white cubs were born at the St. Augustine Wild Reserve in north Florida to a 14-year-old, infirm heterozygous tigress named Bindhi (Pers. Obs.). The father of the cub is a white eight-year-old tiger. This tigress was a rescue, and unknown to the Reserve, was pregnant and suffered from a failing pancreas. The male cub remains healthy, but his sister died at five weeks of age from a large hole in the septum of her heart, which divides the left and right ventricles. This deformity is a direct result of inbreeding, compounded by Bindhi's ill health. Ultrasound revealed a view of the left and right ventricles, and the enormous hole that caused her heart to

enlarge to the point that it filled up most of her upper chest and she finally went into cardiac arrest.

Dr. Teresa DeFrancesco, Associate Professor in Cardiology at North Carolina State University College of Veterinary Medicine, reviewed the ultrasound that was performed on Eywa. Dr. DeFrancesco confirmed that Eywa had severe congenital heart disease with ventricular septal defect (VSD). When Eywa was transported to a clinic in Florida for treatment, the attending veterinarian prescribed diuretics. Dr. DeFrancesco believes that these diuretics lowered Eywa's cardiac output to a point insufficient with life. She also may have developed a viral or infectious disease process, since she also had a fever of 105 degrees F.

Ultrasound revealed a large membranous VSD (0.5cm) (Fig. 3\*). The tiger cub also had moderate to severe aortic insufficiency, and moderate mitral valve and tricuspid valve insufficiencies. The aortic insufficiency is a common sequela of VSD. The high velocity flow between the left and right ventricles essentially sucks the aortic valve leaflet. This aortic insufficiency further contributed to Eywa's severe heart enlargement and workload. The mitral and tricuspid valve insufficiencies could have been a result of the dilation of her heart and the stretching of the mitral valve annulus. Eywa may have had

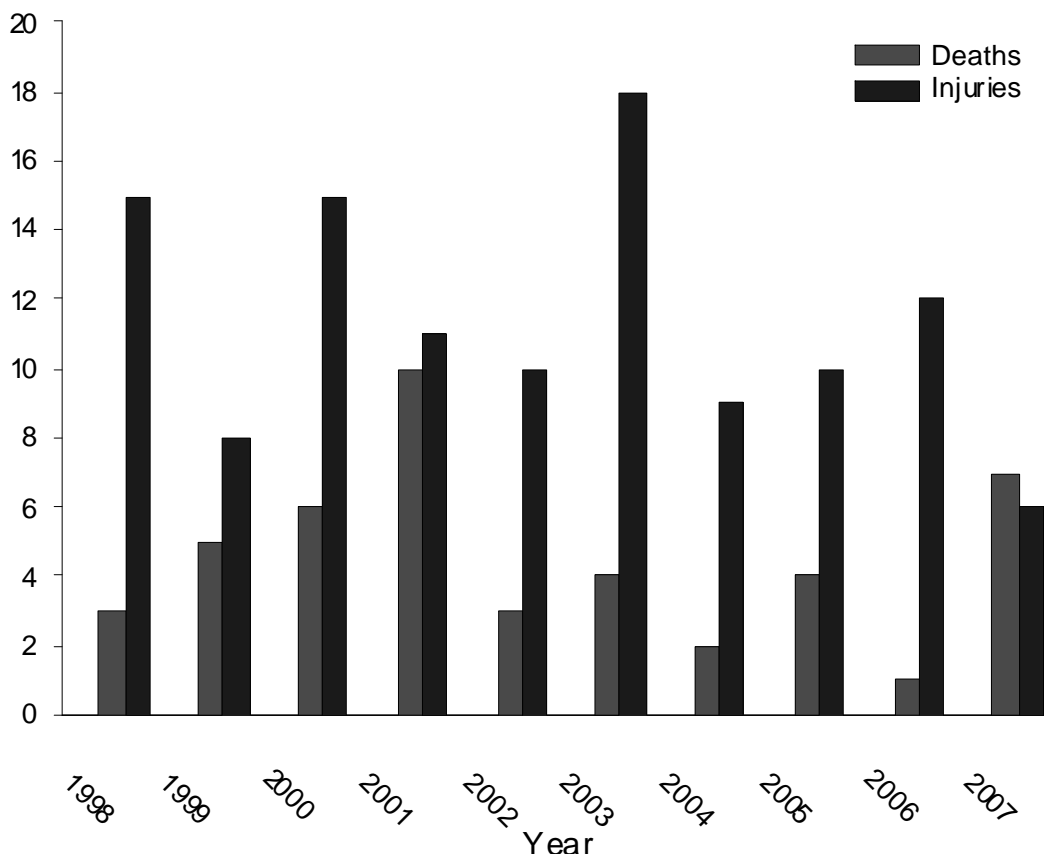
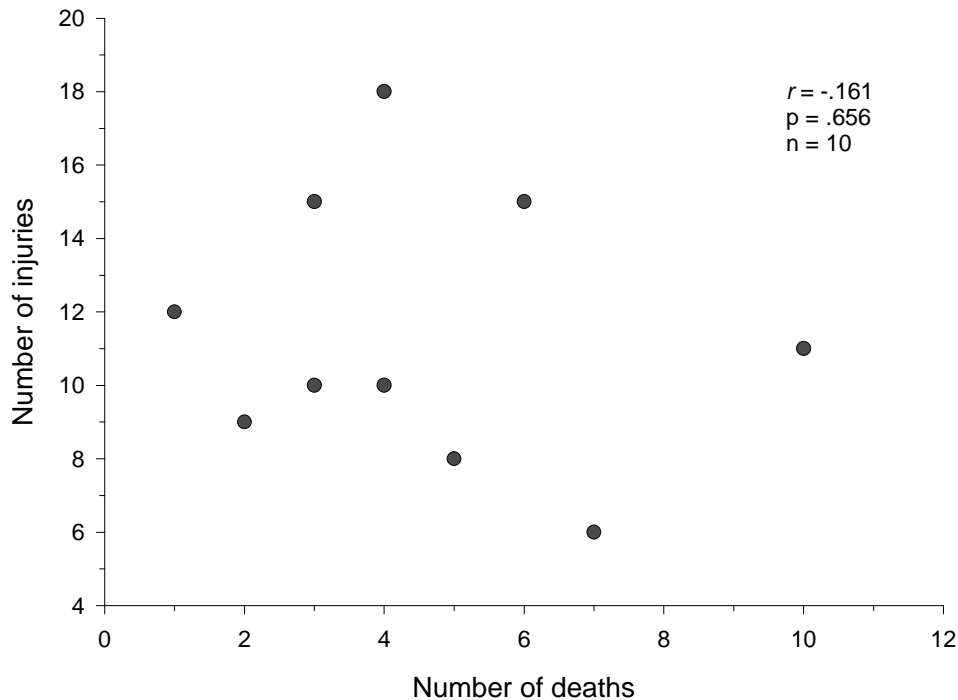


Figure 4. Number of people worldwide killed/injured by captive tigers from 1998-2007

## Relationship between deaths and injuries caused by captive tigers 1998-2007



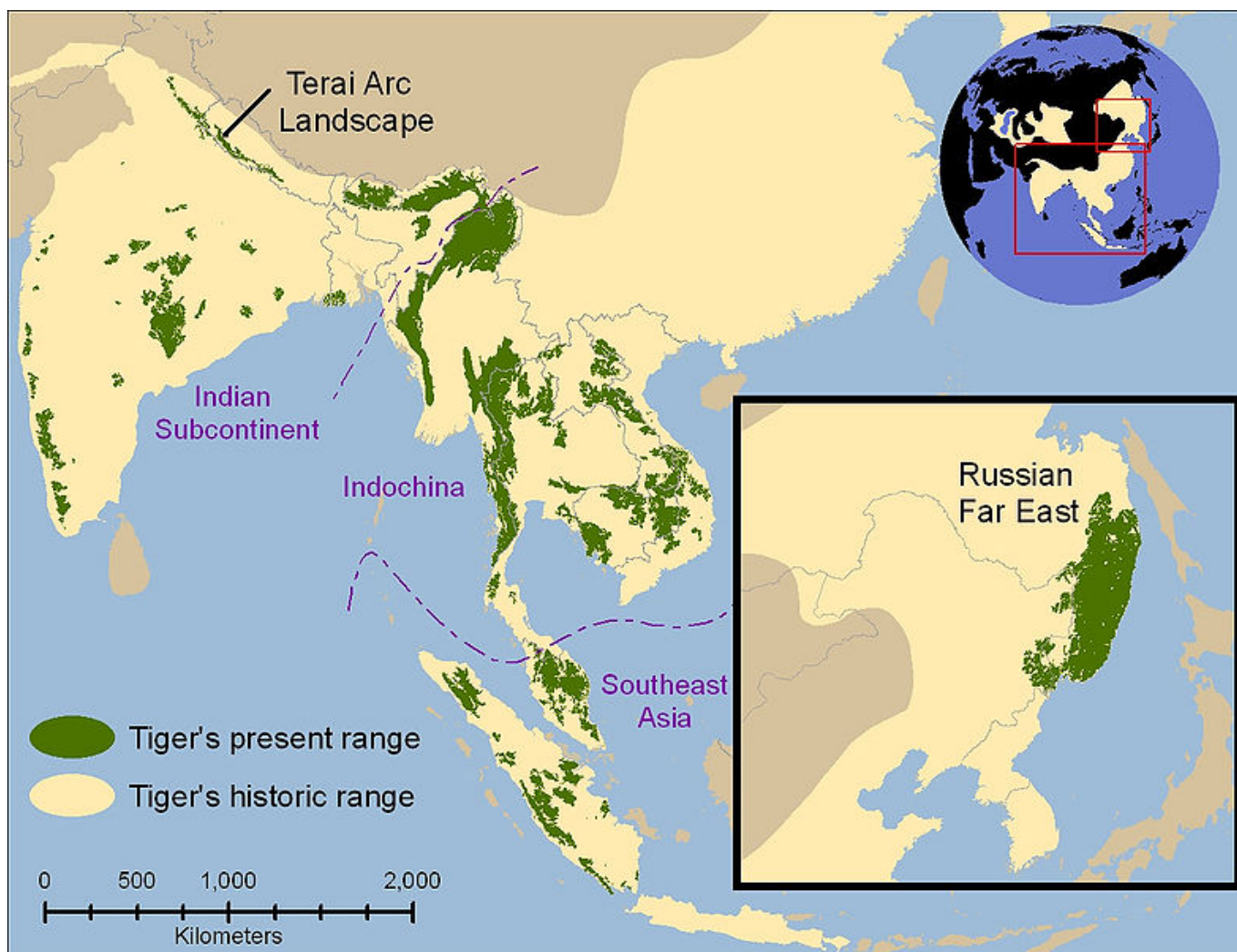
**Figure 5. Relationship between deaths and injuries caused by captive tigers. There is a slight slope, but not enough to be statistically significant since P (the probability of significance) is greater than .05 and the regression coefficient is nearly zero.**

dysplasia of the mitral and tricuspid valves as well. Surgical repair of Eywa's heart could not have been accomplished with minimally-invasive techniques. The clamshell or Amplatz devices that are used for VSD's must have at least a few millimeters of ventricle to grab on either side of the hole. Eywa's VSD was just under her aortic valve, so she was not a candidate for that minimally-invasive procedure. She should have been prescribed congestive heart failure medications, such as pimobendan, enalapril or furosemide, which may have extended her life for a while. If the patient were a human baby, the medications would have stabilized her until open heart surgery could be performed. However, before any surgery, more thorough evaluations would have been performed on Eywa, including a more complete echocardiographic study with Doppler evaluation of each valve, and a possible angiography. Open heart surgery is only offered in a couple of places for veterinary patients. Colorado State university and the University of California at Davis offer the procedure, and generally charge \$10,000 or more per case. Had Eywa even survived such a surgery, healing would have been a steep, uphill battle for her.

*Caudal Cervical Disc Protrusion:* Caudal cervical disc protrusion in an eight-year-old Bengal tiger (*Panthera tigris tigris*) was observed at a compound

in South Africa (Lambrechts, *et al.*, 2000). The white tiger suffered from hind limb ataxia and thoracolumbar pain, evidenced by its severely arched back and knuckling-over of the animal's pelvic limb paws. X-rays showed a narrowing of the C6-7 intervertebral disc space. Mild ventral spondylosis was observed. The tiger was placed in confinement and given prednisolone. Improvement was observed, however, clinical signs returned as soon as the tiger was placed back into its enclosure and drug therapy was stopped. Surgery was performed followed by an extensive recovery period, not without complications. This type of malady is usually seen in dogs, and appears to be the first report of this condition in tigers. The congenital abnormalities common in white tigers may have been linked to this discovery of caudal cervical disc protrusion.

*Problems with anesthesia:* Although it is risky to sedate tigers of any color, the white tigers are more susceptible to problems under anesthesia, since they produce a mutated form of tyrosinase, the enzyme responsible for making melanin. This copper-protein enzyme facilitates the oxidation of tyrosine to dopa, and of dopa to dopaquinone. White tigers may experience a re-sedation effect 24 to 36 hours after they have been sedated (Tilson, 1987).



**Figure 5. Historic (circa 1850) and present tiger distribution. Tigers became extinct on Bali around 1940 and on Java in around 1980. At one time, tigers inhabited portions of central Asia around the Caspian Sea (see inset globe) but were extirpated in the 1970's. (Dinerstein, *et al.*, 2007).**

Ketamine will cause as many as three grand mal seizures, excessive salivation, and a prolonged recovery period (Pers. Obs.). The use of Telazol (tiletamine and zolazepam) is also dangerous to all tigers, including white tigers. Recovery could take hours or days, neurological signs have been observed, and there have been reports of death from the use of this drug (Vogelnest 1999).

#### **Dangers Associated With Inbreeding**

All captive tigers have the propensity to attack their handlers, whether they are white or orange (Fig. 4). Taming an animal is different from domesticating an animal, the latter of which takes thousands of years. Many animal trainers who have worked with white tigers observed the fact that white tigers tend to be more dangerous than orange tigers. Part of this may be due to the tiger's inability to see properly. They tend to spook more easily and attack. Additionally, inbreeding produces an unstable temperament, as seen in studies with foxes. An unstable temperament may trigger an

attack from aggression or from fear. Inbreeding causes both of the common ancestor's recessive genes, which may hold a tendency toward aggression, to be expressed (Kukekova 2008).

The popular Las Vegas Act, Siegfried and Roy, was halted permanently when Montecore, one of their male white tigers, bit Roy Horn on the neck and dragged him off stage. Horn suffered extensive damage and is still recovering.

Number of people worldwide killed/injured by captive tigers from 1998-2007 (Fig. 4). There were 159 attacks (114 injuries and 45 deaths), which is an average of 4.5 deaths and 11.4 injuries per year. The reported number of deaths is most likely accurate, since human death is a high-profile media concern. The reported number of injuries is underestimated, since these injuries are often not discovered by the media, in an effort to maintain confidentiality at the zoological institution where the injury occurred (Tilson, *et al.*, 2010).

Cat Dancers Joy and Ron Holliday performed on stage with leopards, jaguars and tigers, along with their partner, Chuck Lizza. Cat Dancers became one of the world's first exotic-tiger entertainment acts. Chuck was killed by an adult white tiger that was hand-raised by the trio from birth, when he tripped and fell in front of the animal while it was out of its cage. Joy was killed three weeks later when she approached the tiger while she was in a fragile state. She had lost much weight and was despondent over the loss of Lizza. Their white tiger immediately grabbed Joy and tossed her into the air; she was dead before she hit the ground. Ron Holliday attributes the tiger's behavior to inbreeding.

A correlation was prepared for Fig. 4 to determine if the number of deaths was correlated with the number of injuries (Warrick, 2010) (Fig. 5\*). The number of deaths cannot predict the number of injuries.

### **Methods for Purifying Tiger Lineages**

The responsibility of purifying the white tiger line lies with private animal compounds, which would maintain the white tiger's value in tiger conservation. A breeding program of this magnitude would require educating all tiger owners about how to properly breed their animals to avoid further inbreeding maladies. An easy solution would be to outbreed white tigers to pure orange tigers, or breed only distantly-related heterozygous individuals. This practice of out-crossing would introduce new genes, increase vigor, improve immune system function and fecundity, and over time would expunge deleterious traits. Another method to reverse the effects of inbreeding and to slow vigor loss is to line-breed white tigers to orange tigers for two or three generations, and then out-cross the progeny to an unrelated line, which would increase genetic diversity and hybrid vigor.

The Florida panther (*Puma concolor coryi*) had dwindled in numbers until only 30-50 adults were left in the wild by 1981. The remaining panthers exhibited signs of inbreeding depression, including congenital heart defects, cryptorchidism, kinked tails and poor sperm quality. In 1995, eight female Texas cougars (*Puma concolor stanleyana*) were released into Florida to increase genetic variability of the Florida panther. By 2001, the restoration program was declared successful (PantherNet 2010). There was a reduction in the occurrence of inbreeding as five of the original eight female cougars from Texas bred with the existing population of Florida panthers and produced over 30 cubs. In just a few short years, the Florida panther was rescued from the brink of extinction. This population management technique could be used with white tigers and possibly experience the same success rate.

Purifying the white tiger lineage would increase the conservation value of captive tigers held in private compounds. There is no data on how much genetic diversity these captive tigers possess. They may even be more diverse than their wild cousins. It would be difficult to reintroduce white tigers into the wild, since they would be shot as trophy animals, plus there really is no suitable location for any tiger release. Tigers require large prey as a food source and a region unoccupied by humans. Even in protected national parks, poachers do not respect such boundaries and will poach not only tigers, but also the very animals that tigers prey upon. Human population densities are increasing; tiger habitats will quickly erode as the demand for food and natural resources to feed *Homo sapiens* increases exponentially. Tiger habitat has decreased 41% over the past decade, leaving this predator with only 7% of their historical range (Dinerstein, *et al.*, 2007) (Fig. 5).

Further, tigers raised in captivity lack skills that are necessary to hunt prey and kill it efficiently (Norris, 2005). However, all tigers, no matter what their color, are valuable as ambassadors to their species and offer some insurance, should the wild tiger become extinct (Shu-Jin, *et al.*, 2008). To see, hear and observe a tiger up close and personal in a sanctuary setting is crucial in educating the public about tigers and their place in the ecosystem. Only with this close contact will the public realize that to support the illegal trade in tiger parts and medications made from tigers, will surely result in the extinction of this magnificent carnivore. A well-managed captive tiger population can also assist in raising funds for wild tiger protection, since individuals who visit zoos and sanctuaries become aware of the various organizations who are involved in protecting wild tigers and their habitat. The impact on tourism in countries such as India would be high, since observing a wild tiger while riding upon the back of an elephant is a popular tourist draw.

Captive white and orange tigers are routinely anesthetized for various surgical procedures. Such anesthetic protocol is invaluable for researchers of wild tigers who must anesthetize their subjects for study, or to attach radio collars. As previously mentioned, the white tiger once was fairly prevalent in the wild, and deserves a place in bonafide tiger conservation programs.

### **Conclusion**

The novelty of exhibiting white tigers over the past 60 years has led to severe inbreeding depression in this mutation. As wild tiger habitat continues to decrease and poaching removes the last of *Panthera tigris* from our wild world, there is no choice except to propagate all tiger subspecies and color variants in captivity. Out crossing white tigers to unrelated orange tigers will result in fitness recovery. Fitness may even be enhanced over the



original non-inbred fitness levels for a time, creating heterosis (hybrid vigor). This applies to all loci that are fixed for different alleles in the two tiger populations. Fitness will inevitably exhibit a reduction in subsequent generations, as allele segregation results in homozygotes.

Until we create a perfect world, where Chinese medicine does not value a dead tiger over a live specimen because of its pseudo-aphrodisiac properties, and the wealthy are satisfied with quaffing a fine Pinot Noir instead of Tiger Bone Wine, the only hope for this species is captive propagation and purging of deleterious alleles. When the last tiger disappears from the forests of India, Southeast Asia, Indochina and the Russian Far East, its roar and chuff forever gone from its once pristine range, *Homo sapiens* will still be privileged to view live tigers in man-made habitats. Hope exists that our descendants will one day respect this resplendent predator and return it to the wild where it will be free from persecution, superstition, and archaic cultural beliefs, its roar and chuff once again dominating the world's forests.

#### References

**Devraj, Ranjit (2000).** Environment-India: inbreeding threatens white tiger. *Environment Bulletin*, Item 00220001, *Academic OneFile*.

**Dinerstein, Eric, Loucks, Colby, Wikramanayake, Eric, Ginsberg, Joshua, Sanderson, Eric, Seidensticker, John, Forrest, Jessica, Bryja, Gosia, Heydlauff, Andrea, Klenzendorf, Sybille, Leimgruber, Peter, Mills, Judy, O'Brien, Timothy G., Shrestha, Mahendra, Simons, Ross, and Songer, Melissa, (2007).** The fate of wild tigers. *BioScience*, 57, Issue 6, 508-514.

**Frankham, R., Ballou, J.D., and Briscoe, D.A. (2003).** Introduction to Conservation Genetics. Cambridge University Press, New York, NY, p. 303.

**Gates, Margaret (2010).** Nutrition. *Feline Nutrition Education Society*. {[www.feline-nutrition.org](http://www.feline-nutrition.org)}.

**Hernandez, E. Herrero (2009).** On the track of the white tiger: pigmentation could be linked to prion diseases, and location explains why. *Medical Hypotheses*, 73, 309-311.

**Jones, Bretaigne (2010).** Fetal development & birth defects in cats. *Scientific Communications*, Royal Canin, USA. [http://www.royalcanin.us/library/fetal\\_development\\_birth\\_defects\\_cats.aspx](http://www.royalcanin.us/library/fetal_development_birth_defects_cats.aspx)

**Kelly DF, Pearson H, Wright AI, Greenham LW. Morbidity in captive white tigers (1980).** In: Montali RJ, Migaki G, editors. *The Comparative Pathology of Zoo Animals*. Washington, DC: Smithsonian Institution Press; 1980. 83-188.

**Ketz, Cornelia J., Radlinsky, MaryAnn, Armbrust, Laura, Carpenter, James W., and Isaza, Ramiro, (2001).** Persistent right aortic arch and aberrant left subclavian artery in a white Bengal tiger (*Panthera tigris*). *Journal of Zoo and Wildlife Medicine*, 32, Issue 2, 268-272.

**Kukekova, Anna, Trust, L.N., Chase, K., Shepeleva, D.V., Vladimirova, A.V., Kharlamova, A.V., Oskina, I.N., Stepika, A., Klebanov, S., Erb, H.N., Acland, G.M. (2008).** Measurement of segregating behaviors in experimental silver fox pedigrees. *Behavior Genetics*, 38,185.

**Lambrechts, Nic E., Berry, Wayne L. (2000).** Caudal cervical disc protrusion in a Bengal tiger (*Panthera tigris tigris*). *Journal of Zoo and Wildlife Medicine*, 31(3), 404-407.

**Luo, Shu-Jin, Johnson, Warren E., Martenson, Janice, Antunes, Agostinho, Martelli, Paolo, Uphrykina, Olga, Traylor-Holzer, Kathy, Smith, James L.D., O'Brien, Stephen J. (2008).** Subspecies genetic assignments of worldwide captive tigers increase conservation value of captive populations. *Current Biology*, 20, Issue 8, 592-596.

**Mills, Margaret G., Patterson, Larissa B. (2009).** Not just black and white: pigment pattern development and evolution in vertebrates. *Seminars in Cell & Developmental Biology*, 20, 72-81.

**Norris KM. (2005).** Born to be wild: Tiger persecution and advocacy from 1800 to the present. Master's thesis. Virginia Polytechnic Institute and State University, Blacksburg,VA.

**PantherNet (2010).** Florida Panther Handbook, *Florida Fish and Wildlife Conservation Commission*, [www.floridapanthernet.org](http://www.floridapanthernet.org).

**Rathore, B. and S. Khera (1979).** Causes of deer mortality in India. *Journal of the Bombay Natural History Society*, 78(1):156-159.

